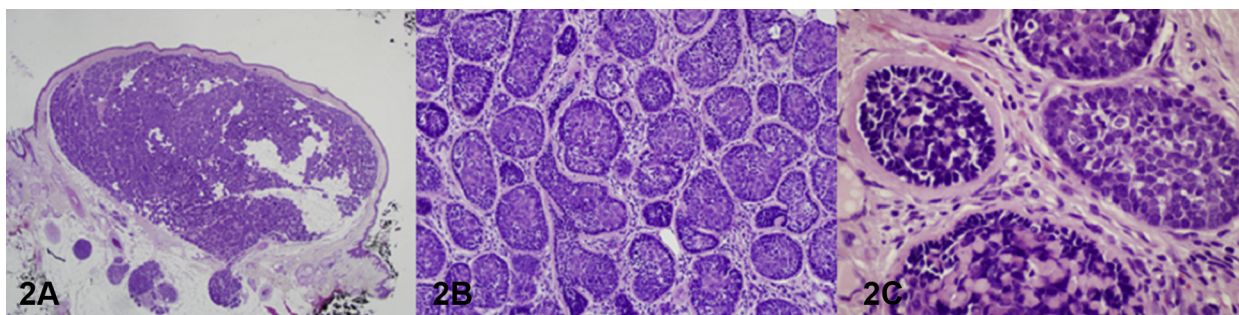
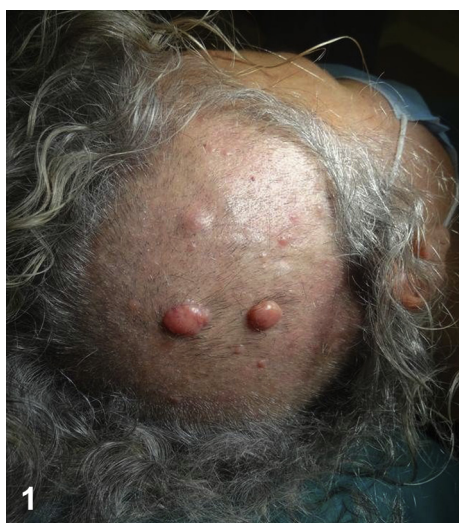

Multiple rubbery nodules on the scalp



Roberto Russo, MD,^a Astrid Herzum, MD,^a Emanuele Cozzani, MD, PhD,^a Michele Paudice, MD,^b
Antonio Guadagno, MD,^b and Aurora Parodi, MD^a
Genoa, Italy

Key words: adenocarcinoma; Brooke-Spiegler; CYLD; cylindroma; spiradenoma; trichoepithelioma.



A 60-year-old woman presented with two slowly-growing pink, firm, rubbery nodules on her scalp. She had a personal history of acral melanoma and of spiradenomas and trichoepitheliomas of the scalp. Her familial history was negative for skin tumors. Physical examination found numerous pink, red, and bluish smaller nodules on her scalp (Fig 1). The two larger nodules were surgically excised; histologic examination showed lobular structures in a jigsaw puzzle pattern with focal subcutaneous extension, each well circumscribed by a hyaline basement membrane. Palisading peripheral small cells showed hyperchromatic nuclei; central cells were larger, with vesicular nuclei. No pleomorphism, necrosis, or mitoses were found (Fig 2).

From the DiSSal Section of Dermatology^a and the Section of Pathology,^b San Martino Polyclinic Hospital IRCCS, University of Genoa.

Funding sources: None.

IRB approval status: Not applicable.

Correspondence to: Astrid Herzum, MD, University of Genoa, DiSSal Section of Dermatology, San Martino Polyclinic Hospital IRCCS, Largo Rosanna Benzi, 10, 16132 Genoa, Italy.
E-mail: astridherzum@yahoo.it.

JAAD Case Reports 2021;8:80-2.

2352-5126

© 2020 by the American Academy of Dermatology, Inc. Published by Elsevier, Inc. This is an open access article under the CC BY-NC-ND license (<http://creativecommons.org/licenses/by-nc-nd/4.0/>).

<https://doi.org/10.1016/j.jdc.2020.12.023>

Question 1: Which is the most likely diagnosis?

- A. Sebaceous carcinomas
- B. Trichilemmomas
- C. Cylindromas
- D. Amelanotic melanomas
- E. Neurofibromas

Answers:

A. Sebaceous carcinomas—Incorrect. Extraocular sebaceous carcinomas typically appear as pink to yellow-red nodules of varying size. Histologically dark basaloid cells mixed with more mature sebaceous cells in an irregular architecture retaining connection to the epidermis are typical. Necrosis and mitoses are abundant.^{1,2}

B. Trichilemmomas—Incorrect. Trichilemmomas usually present on the face, ears, and neck as skin-colored, slowly-growing papules, coalescing into warty plaques. Microscopically, dermal lobules composed of palisading peripheral small cells and squamous vacuolated glycogen-rich cells are connected to the follicular epithelium or epidermis.^{1,2}

C. Cylindromas—Correct. Cylindromas, solitary or multiple, usually arise on the scalp as firm, rubbery, pink-to-red or bluish papulonodular lesions. When they are numerous, covering the entire scalp, they cause hair loss (“turban tumor”). Histologically they consist of dermal nodules without connection to the overlying normal-appearing epidermis. Subcutaneous extension may occur. They show lobular growth with a typical jigsaw puzzle pattern. A thick periodic acid-Schiff-positive basal membrane covers each lobule characterized by peripheral palisading of small hyperchromatic cells and larger central cells with vesicular nuclei. Cellular pleomorphism and mitoses are usually absent.¹⁻³

D. Amelanotic melanomas—Incorrect. Any subtype of melanoma can be amelanotic, presenting as a macule or nodule that can be skin-colored, pink, or red. Microscopically they mimic melanocytic and nonmelanocytic proliferations. Immunohistochemistry may establish the melanocytic differentiation.^{2,4}

E. Neurofibromas—Incorrect. Neurofibromas may present as skin-colored, soft-to-firm papules or nodules with a smooth surface. The “buttonhole invagination” is typical: a finger pressing on the

lesion causes its invagination. Microscopically they consist of spindle cells in a fibrillar or myxoid stroma. Numerous small nerve fibers are present.^{1,2}

Question 2: Which syndrome would you suspect?

- A. Muir-Torre syndrome
- B. Cowden syndrome
- C. Brooke-Spiegler syndrome
- D. Tuberous sclerosis
- E. Type I neurofibromatosis

Answers:

A. Muir-Torre syndrome—Incorrect. Muir-Torre syndrome is a form of Lynch syndrome and is characterized by sebaceous skin tumors in association with internal malignancies, mainly colorectal cancers.¹

B. Cowden syndrome—Incorrect. Patients with Cowden syndrome usually develop trichilemmomas on their face along with oral papillomas; they may also have epidermal nevi, lipomas, and café-au-lait spots. These patients have an increased risk of malignancies, including skin squamous cell carcinomas.⁵

C. Brooke-Spiegler syndrome—Correct. Brooke-Spiegler syndrome is a rare autosomal dominant syndrome with numerous adnexal tumors, mainly localized on the scalp and face, histologically corresponding to spiradenomas, cylindromas, and trichoepitheliomas. Malignant transformation of lesions occurs in 5% to 10% of patients, heralded by rapid tumor growth, bleeding, or ulceration.

The occurrence of malignant transformation of trichoepithelioma into basal cell carcinoma is very rare or even questioned by some authors, arguing it actually represents unrecognized cases of basal cell carcinoma or collisions of two independent neoplasms, namely basal cell carcinoma and trichoepithelioma.

Additionally, patients have an increased risk of developing adenocarcinoma of the salivary glands. Regular clinical follow-up is fundamental, as the risks of malignant transformation and disease severity are not assessable *ex ante* on the basis of only genotypic and phenotypic characteristics. Acral melanoma was a casual association in our case.³

D. Tuberous sclerosis—Incorrect. The cutaneous features of tuberous sclerosis are, among others, ash

leaf spots, facial angiofibromas, and Koenen periungual tumors.⁵

E. Type 1 neurofibromatosis—Incorrect. Skin findings in type 1 neurofibromatosis include neurofibromas as well as café-au-lait spots and freckles.⁵

Question 3: Which gene(s) play a role in this condition?

- A.** MLH1 and MSH2
- B.** PTEN
- C.** CYLD
- D.** TSC1 and TSC2
- E.** NF1

Answers:

A. MLH1 and MSH2—Incorrect. These are the genes implicated in Muir-Torre syndrome. They are involved in mechanisms of DNA repair.¹

B. PTEN—Incorrect. PTEN is a tumor suppressor gene acting via its phosphatase protein product. More than 70 different mutations of PTEN are implicated in the pathogenesis of Cowden syndrome.⁵

C. CYLD—Correct. Mutations in this gene have been associated with Brooke-Spiegler syndrome, multiple familial trichoepithelioma, and cylindromatosis. CYLD is a tumor suppressor gene that

negatively regulates NF- κ B and JNK signaling pathways and mediates, through RIP1 deubiquitination, caspase-dependent apoptosis. A mutation of the CYLD gene was detected in a blood sample of the described patient.³

D. TSC1 and TSC2—Incorrect. These genes are involved in the pathogenesis of tuberous sclerosis.⁵

E. NF1—Incorrect. An NF1 mutation is responsible for the development of type 1 neurofibromatosis, as it encodes a protein known as neurofibromin, which plays a role in cell signaling, as a negative regulator of the Ras oncogene signal transduction pathway. TSC1 and TSC2 are both tumor suppressor genes, coding for hamartin and tuberlin, respectively.⁵

Conflicts of interest

None disclosed.

REFERENCES

1. Elder DE, Massi D, Scolyer RA, Willemze R, eds. *WHO Classification of Skin Tumours*. 4th ed 11. 2018.
2. Calonje E. *McKee's Pathology of the Skin with Clinical Correlations*, chapter 31-33, 35. Elsevier; 2020.
3. Mohiuddin W, Laun J, Cruse W. Brooke-Spiegler syndrome. *Eplasty*. 2018;18:ic14.
4. Gong HZ, Zheng HY, Li J. Amelanotic melanoma. *Melanoma Res*. 2019;29:221-230.
5. Holman JD, Dyer JA. Genodermatoses with malignant potential. *Curr Opin Pediatr*. 2007;19:446-454.